

Received 2021-07-03

Revised 2021-09-24

Accepted 2021-11-01

Evaluating the Safety of Electroconvulsive Shock and Duloxetine Combination Therapy on Behavioral, Cardiovascular, and Brain Oxidative Stress Markers in the Mice

Bahareh Eghbal^{1,2}, Ava Soltani Hekmat², Seyed Amin Kouhpayeh³, Ali Ghanbariasad^{4,5}, Kazem Javanmardi², Nastaran Samimi^{1,4}, Bahareh Fakhraei^{4,6}, Mojtaba Farjam⁴✉

¹ Student Research Committee, Fasa University of Medical Sciences, Fasa, Iran

² Department of Physiology, School of Medicine, Fasa University of Medical Sciences, Fasa, Iran

³ Department of Pharmacology, Fasa University of Medical Sciences, Fasa, Iran

⁴ Noncommunicable Diseases Research Center, Fasa University of Medical Sciences, Fasa, Iran

⁵ Department of Medical Biotechnology, School of Advanced Technologies in Medicine, Fasa University of Medical Sciences, Fasa, Iran

⁶ Department of Psychiatry, School of Medicine, Fasa University of Medical Sciences, Fasa, Iran

Abstract

Background: Electroconvulsive Therapy (ECT) as a well-established and effective therapeutic approach for the treatment of various psychiatric disorders is an excellent option to treat major depressive disorder (MDD). The goal of this experimental study was to determine the possible side effects of electroconvulsive shock (ECS) and duloxetine, a serotonin-norepinephrine Reuptake Inhibitors (SNRIs), and evaluate the safety of this therapeutic approach on behavioral factors, cardiovascular function, and brain oxidative stress markers on mice. **Materials and Methods:** Animals were divided into different groups receiving either ECS or different doses (10, 20, 40, 80, or 120 mg) of duloxetine alone or together. We evaluated the behavioral factors associated with the administration of ECS with or without duloxetine. In addition, we monitored the electrocardiogram (ECGs) of animals prior to and after the experiment and also evaluated the oxidative stress markers including TAC, MDA, and GSH mice's brains. **Results:** According to our results, there are no life-threatening cardiac arrhythmias or cardiac arrests associated with the combination therapy of ECS and duloxetine. We did not detect any significant differences in terms of heart rate, RR interval, PR interval, QT, or corrected QT (QTc) between groups that received different doses of duloxetine in combination with ECS compare to the control group. Our findings suggest that while administration of ECS solely increased the oxidative stress markers and decreased the antioxidant capacity of the brain, a combination of duloxetine and ECS at certain doses alleviates the oxidative stress condition and increases the antioxidant capacity of the brain. **Conclusion:** Overall, this study suggests that the combination of ECS and duloxetine is safe and considerable for further studies on human subjects. [GMJ.2021;10:e2218] DOI: [10.31661/gmj.v10i0.2218](https://doi.org/10.31661/gmj.v10i0.2218)

Keywords: Electroconvulsive Therapy; Duloxetine; Depression; Major Depressive Disorder; Oxidative Stress; Depression

GMJ

Copyright© 2021, Galen Medical Journal. This is an open-access article distributed under the terms of the Creative Commons Attribution 4.0 International License (<http://creativecommons.org/licenses/by/4.0/>)
Email: info@gmj.ir



✉ Correspondence to:

Mojtaba Farjam, Non-communicable Diseases Research Center, Fasa University of Medical Sciences, Ibn-Sina Square, Fasa, Fars, Iran

Telephone Number: +98-715-3314068

Email Address: mfarjam@fums.ac.ir

Introduction

Depression is a serious yet common mental disorder affecting many adults worldwide. As reported by the World Health Organization (WHO), globally, more than 264 million people struggle with depression. The fourth widespread disease globally is a significant burden [1]. While this disease can cause various symptoms, according to the fifth edition of the Diagnostic and Statistical Manual of Mental Disorders (DSM-5), the diagnosis would be confirmed if the symptoms meet at least 5 of the criteria for more than 2 weeks period. Their criteria include: depressed mood, anhedonia, significant appetite or weight change, agitation or retardation, sleep disturbance, feelings of worthlessness, decreased energy level, difficulty in concentration, suicide, or death thoughts [2]. Electroconvulsive Therapy (ECT) is one of the best and most effective ways to treat the major depressive disorder (MDD). This method is prescribed for treating depression when none of the drug treatment methods has been influential on the patient. ECT involves inducing a seizure through electrodes placed on a patient's scalp [3]. Studies have shown that ECT is safe. However, some complications such as persistent cognitive impairment (impairment in brain functions such as memory and language, etc.), confusion, and headache are accounted as its rare side effects [4]. Treatment-resistant depression (TRD), the most severe type of depression, is a type of major depression defined as the lack of adequate response to high doses of two or more antidepressant therapy in a standard treatment period. Guidelines from the National Institute for Clinical Excellence (NICE) suggest that dose or drug alteration, adding more antidepressants, psychotherapy or ECT could benefit these patients [5]. Serotonin-norepinephrine Reuptake Inhibitors (SNRIs) are a group of antidepressants widely used to treat TRD. Among them, Duloxetine has promising effects on TRD treatment. On the other hand, ECT is widely acknowledged as an essential part of TRD treatment [6]. Studies suggest that a combination therapy consisting of SNRI and

ECT is far more effective than using one of the mentioned treatments alone [7].

Although few cases reports approved the safety of duloxetine and ECT combination therapy, no animal studies or clinical trials support the safety of this approach of treatment [8, 9]. However, some evidence is that combining other SNRI drugs with ECT to treat TRD in some doses may lead to cardiovascular complications such as asystole and ventricular tachycardia [10, 11]. We aimed to evaluate treatment safety with different doses of Duloxetine in combination with ECS therapy on behavioral markers, cardiovascular function, and brain oxidative stress markers in the mice model.

Methods and Materials

Animals

Experiments were carried out on 105 male BALB/c mice with an average age of 6 weeks, weighing 25-40 mg. The animals were provided by the animal laboratory of Fasa University of Medical Sciences and housed in a standard laboratory environment (temperature $22\pm 1^{\circ}\text{C}$, 50-60% humidity, and 12:12 hours light/dark cycle) with free access to water and food. 10 days before the experiment, they were handled daily to reduce their stress.

91 animals were randomly divided into the following groups (each group consists of 7 mice):

-Saline: Mice were orally treated with normal saline every 12 hours for 2 days.

-Salin+ECS: Mice received normal saline and ECS. Animals were orally treated by normal saline every 12 hours for 2 days.

-DUL: These groups were treated with different doses of Duloxetine without receiving ECS. Each group included 7 mice and received 10, 20, 40, 80, or 120 mg of Duloxetine every 12 hours for 2 days.

-DUL+ECS: These groups received both ECS and different doses of Duloxetine. Each group included 7 mice and received 10, 20, 40, 80, and 120 mg of Duloxetine in addition to ECS. Mice were orally treated with Duloxetine every 12 hours for 2 days.

-PHT+ECS: This group received 60 mg of

phenytoin in addition to ECS. Mice were orally treated with phenytoin every 24 hours for 4 days (due to its length (22 hours) half-life compare to Duloxetine (12 hours)).

Drugs

Several drugs were used in this experiment, including Duloxetine (DULOXETINE-HAKIM, Iran) and phenytoin (PHENYTOIN-ALHAVI, Iran). All drugs were dissolved in distilled water and prepared daily as new solutions according to the required concentrations and weight of the mice. In the case of Duloxetine, which is available in capsules containing granules, we first powdered the granules and then dissolved them.

Electrocardiogram (ECG) Analysis

Animals were anesthetized by ketamine (KETAMIN ROTEXMEDICA, Germany, 80 mg/kg) and xylazine (ANASED, New Zealand, xylazine 10 mg/kg) intraperitoneal injections. The ECGs were monitored by PowerLab (ADInstruments, Australia) in the lead II. The green electrode is attached to the left arm, the black electrode to the right arm, and the red electrode to the left leg. The recorded ECGs were analyzed by LabChart software. Three ECGs were obtained from each animal before inducing anesthesia and after ECS induction. In the groups that did not receive ECS and were only treated by pharmacological treatments such as Duloxetine and phenytoin, we monitored the ECGs at their maximum plasma concentration, approximately 6 hours for both mentioned drugs. Indicators such as heart rate, PR interval, RR interval, QT interval, and QTc were evaluated to assess the effects of mentioned pharmacological and ECS interventions on cardiac activity.

Administration of Electroconvulsive Shock

Inducing seizure by ECT is a well-known animal model mimicking tonic-clonic convulsion in rodents [12]. Auricular electrodes were applied (100 HZ, 60 mA, 1 sec) to simulate seizures electrically [13]. We recorded the seizures by the camera, and the duration of total seizure time, tonic and clonic seizures, and myoclonic jerks were analyzed

over 5 min in each animal. The intensity of seizures was analyzed according to the scale described in Table-1.

Oxidative Stress Evaluation

After inducing seizures and monitoring the second ECG, we deepened the anesthesia and sacrificed the animals following ethical protocol. The brains were removed from the skull weighted and then washed by phosphate buffer saline solution. Hippocampus and cortex were dissected and collected in cryotubes and stored in liquid nitrogen till biochemical assessments.

Due to performing the biochemical tests, 100 mg of each frozen brain tissue was mechanically homogenized in 5 ml of 0.05 M phosphate buffer saline pH 7.4 on ice to prevent heat shock. The homogenized samples were centrifuged (3500 rpm, 15 minutes, and 4°C). Their supernatants were collected and stored at -80°C for further evaluation of tissue total antioxidant capacity (TAC) by ELISA (ZB-TAC-96A, ZellBio GmbH, Germany), malondialdehyde (MDA) by colorimetry (ZB-MDA-96A, ZellBio GmbH, Germany), and glutathione peroxidase (GSH) by ELISA (BXC0551, Biorexfars, Iran).

Ethical Statement

The Ethics Committee approved this study of Fasa University of Medical Sciences (registration number: IR.FUMS.REC.1397.013), and all procedures were performed according to the Helsinki Declaration of 2020 [14].

Results

1. Behavioral Studies

We evaluated the mice's behavioral characteristics after inducing a single seizure by ECS. These characteristics include the total duration of seizure, duration of tonic and clonic phases, and scores in mice. According to Table-2, the whole time of seizure in saline+ECS treated mice is significantly higher compared to the duloxetine 20mg and phenytoin group ($P=0.048$ and $P=0.022$, respectively). Although other treatments reduced the total duration of seizure, the statistical analysis showed no significant

Table 1. Analysis of Seizure Intensity.

Score	Head and mouth movements	Tonic	Clonic	Myoclonic jerks	Standing up and falling	Death
S0	☑	-	-	-	-	☑
S1	☑	☑	-	-	-	☑
S2	☑	☑	-	-	-	-
S3	☑	☑	☑	-	-	-
S4	☑	☑	-	☑	-	-
S5	☑	-	-	☑	-	-
S6	☑	-	-	-	-	-
S7	☑	☑	☑	☑	-	-
S8	☑	☑	☑	☑	☑	-

Table 2. Total Duration of ECS Induced Seizure in Control (Saline+ECS) and Treatment Groups.

Group	Mean duration of the seizure (second) ± SE	P-Value
Saline+ECS	120.14±18.89	-
DUL 10+ECS	53.54±15.58	0.233
DUL 20+ECS	51.62±5.34	0.048*
DUL 40+ECS	99.12±21.03	1
DUL 80+ECS	57.47±10.03	0.341
DUL 120+ECS	72.78±9.26	0.616
PHT 60+ECS	38.54±10.46	0.022*

The treatment groups are compared with the control group. Data were analyzed by one-way ANOVA and Tukey's post hoc test and presented as Mean±SE (*P<0.05). **ECS:** electroconvulsive shock; **DUL:** duloxetine; **PHT:** phenytoin.

Table 3. Duration of ECS Induced Tonic and Clonic Phases of Seizure in Control (Saline+ECS) and Treatment Groups.

Group	Mean duration of tonic and clonic phases (second) ± SE	P-Value
Saline+ECS	31.61±5.1	-
DUL 10+ECS	33.61±5.6	1
DUL 20+ECS	39±6	0.986
DUL 40+ECS	57.32±7.8	0.039*
DUL 80+ECS	24.48±3.3	0.964
DUL 120+ECS	35.15±4.6	1.000
PHT 60+ECS	14.40±3.5	0.533

The treatment groups are compared with the control group. Data were analyzed by one-way ANOVA and Tukey's post hoc test and presented as Mean±SE, (*P<0.05). **ECS:** electroconvulsive shock; **DUL:** duloxetine; **PHT:** phenytoin.

differences in comparison with the control group ($P>0.05$).

Moreover, we measured the duration of the tonic and clonic phases of seizure. Our results showed significant prolongation of tonic and clonic phases in mice treated with 40 mg of Duloxetine compared to the control group ($P=0.039$). The phenytoin-treated group presented decreased Tonic-Clonic duration than the control group; however, their difference was not statistically significant ($P>0.05$, Table-3).

2. Cardiovascular Assessments

2.1. Heart Rate

We monitored animals' heart rate and ECG parameters before and after pharmacological treatments in the presence or absence of ECS therapy. According to our results, although the application of ECS alone reduced mice's heart rate compared to their baseline rates, the results were not statistically significant ($P>0.999$).

Mice that received 20, 40, and 80 mg of Duloxetine in the absence of ECS showed significantly increased heart rate than their baseline heart rate ($P=0.038$, 0.006, and 0.004, respectively). Also, a slight but not significant increase in heart rate was detected in the group treated by 60 mg of phenytoin combined with ECS ($P=0.201$, Figure-1A).

2.2. PR Interval

There were no significant changes in the PR interval before and after interventions among groups ($P>0.05$, Figure-1B).

2.3. RR Interval

Although ECS application prolonged the RR interval, the difference was not statistically significant ($P>0.05$). Administration of different doses of Duloxetine in the absence of ECS reduced the RR interval at some levels. However, only the group that received 40mg of Duloxetine showed a significantly shortened RR interval ($P=0.018$, Figure-1C).

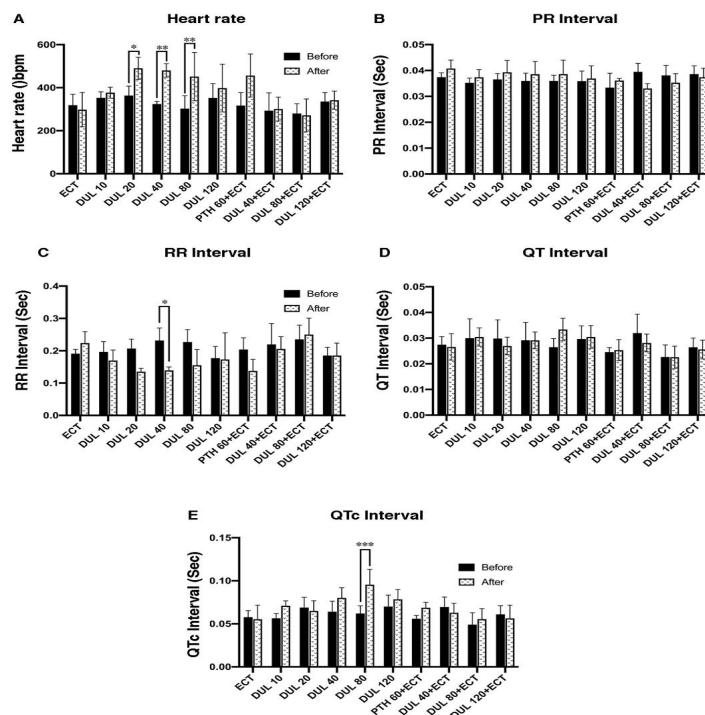


Figure 1. Effects of duloxetine, phenytoin, and ECS on heart rate and ECG indices in control and treatment groups. **A:** comparison of heart rate changes before and after the administration of ECS with or without pharmacotherapy in each group. **B:** comparison of PR interval before and after the administration of ECS with or without pharmacotherapy. **C:** comparison of RR interval before and after the administration of ECS with or without pharmacotherapy. **D:** comparison of QT interval before and after the administration of ECS with or without pharmacotherapy. **E:** comparison of QTc interval before and after the administration of ECS with or without pharmacotherapy. The analysis was performed using Two-way ANOVA and Tukey's multiple comparison post hoc test. Data are presented as mean \pm SD. * $P>0.05$, ** $P>0.01$, *** $P>0.001$. **ECS:** electroconvulsive therapy; **DUL:** duloxetine; **PHT:** phenytoin.

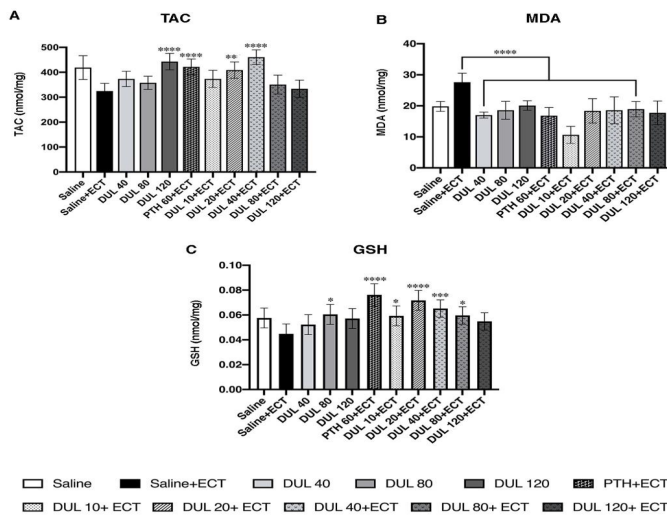


Figure 2. Effects of duloxetine, phenytoin, and ECS on TAC, MDA, and GSH concentrations in control and treatment groups. **A:** comparison of TAC levels (nmol/mg) among all experimental groups. **B:** comparison of MDA levels (nmol/mg) among all experimental groups. **C:** comparison of GSH levels (nmol/mg) among all experimental groups. The analysis was performed using Two-way ANOVA and Tukey's multiple comparison post hoc test. Data are presented as mean±SD. * $P>0.05$, ** $P>0.01$, *** $P>0.001$, and **** $P>0.0001$. **ECS:** electroconvulsive therapy; **DUL:** duloxetine; **PTH:** phenytoin; **TAC:** total antioxidant capacity; **MDA:** Malondialdehyde; **GSH:** glutathione.

2.4. QT and QTc Intervals

We monitored the QT interval before and after the interventions, and our findings showed no significant changes among the experimental groups ($P>0.05$, Figure-1D). In addition, to provide a more accurate assessment of the risk of arrhythmia, we calculated the QTc interval, which allows us to compare the QT values over time at different heart rates. Our data showed significant prolongation of QTc after receiving 80 mg of Duloxetine in the absence of ECS ($P=0.0005$, Figure-1E).

3. Evaluation of Oxidative Stress Markers

As shown in Figure-2, A, the control group that received ECS solely presented the lowest level of TAC. Administration of Duloxetine 120 mg, Phenytoin 60 mg+ECS, Duloxetine 20 mg+ECS, and Duloxetine 40 mg+ECS significantly increased the TAC level ($P>0.0001$, $P>0.0001$, $P>0.0008$, and $P>0.0001$, respectively). These results indicate the destructive effect of ECS on the antioxidant capacity of the brain cortex and hippocampus.

According to our results, administration of ECS alone significantly increased the MDA level in comparison with groups that received Duloxetine 40 mg, Duloxetine 80mg,

Duloxetine 120 mg, Phenytoin 60 mg+ECS, Duloxetine 10 mg+ECS, Duloxetine 20 mg+ECS, Duloxetine 40 mg+ECS, and Duloxetine 80 mg+ECS ($P>0.0001$, Figure-2B). We evaluated the reduced glutathione (GSH) concentration as an antioxidant marker. As expected, the control group that received only ECS showed the lowest level of GSH among all groups. GSH concentrations were significantly higher in Duloxetine 80 mg, Phenytoin 60 mg+ECS, Duloxetine 10 mg+ECS, Duloxetine 20 mg+ECS, Duloxetine 40 mg+ECS, and Duloxetine 80 mg+ECS groups ($P=0.015$, $P>0.0001$, $P=0.036$, $P>0.0001$, $P=0.0004$, and $P=0.027$, respectively, Figure-2C).

Discussion

ECT has been showing promising results for treating many psychiatric disorders and mainly MDD in the past two decades [15]. MDD is one of the most common psychiatric disorders that causes severe depression symptoms which interfere with or limit an individual's social life and personal life. Many MDD affected cases do not adequately respond to pharmacological treatments. There are many approaches for optimal treatment of these patients, and one of the most

effective options is ECT [16]. According to previous studies, patients receiving ECT may present cardiovascular abnormalities such as tachycardia, increased blood pressure, and cardiac output, increasing the risk of cardiac arrhythmia and infarction [17-19].

Moreover, the combination of ECS and venlafaxine show some cardiac complications, such as sinus bradycardia and asystole [20]. Although the ECT+duloxetine combination therapy has been used to treat MDD patients in some cases, this is the first study investigating the safety of this combination by monitoring seizure features and cardiovascular indicators, and brain oxidative stress markers in mice. To explore the safety of this combination, we designed an experimental study on mice. We divided them into 13 groups in which 5 of them received different doses of Duloxetine combined with ECS as the main intervention. Another 5 groups received the same doses of Duloxetine without ECS to find if any behavioral, cardiac, or brain oxidative markers change with the drug in the absence of ECS. One group received saline solution as the vehicle of the drug for comparison with other experimental groups, and another group received only ECS to rule out if any changes in other groups could be independent of the medications and attributable only to the ECS. In addition, we included a group receiving phenytoin to be used as the quality control of the ECS intervention in the experiment. Our results showed a significant reduction of total durations of seizures in the group that received the combination of 20 mg of Duloxetine and ECS compared to those who received ECS alone (who had the highest duration of seizures among all groups).

In addition, the combination of this drug with ECS did not show additional cardiovascular complications compared to ECS therapy alone and appeared to be safe. Our results showed no signs of life-threatening tachyarrhythmias in animals. However, premature atrial contractions (PACs) were detected in all ECS recipient groups. We also evaluated the QT interval as an essential finding of ECG, representing the duration of the ventricles' electrical systole, including ventricular depolarization and repolarization [21].

It is well known that prolonged QT interval increases the risk of arrhythmias such as torsade de pointes, which is a distinctive form of polymorphic ventricular tachycardia. Our results showed no significant prolongation of QTc interval was detected in the ECS+duloxetine groups compared to the control group. We also evaluated the oxidative stress parameters in the brain of animals. It is reported that TAC is lower in the pre-treatment stages of MDD, and pharmacological anti-depressive treatments such as SSRIs and SNRIs can improve the protective elements against oxidative stress [22].

On the other hand, ECS therapy alone can cause oxidative stress-related damages due to neural injury in the brain [23, 24]. MDA originates from polyunsaturated lipid degradation. Measuring the MDA level provides valuable information regarding the extent of lipid peroxidation [25]. The amount of MDA has been reported to be increased due to ECT [26], and TAC was found to be decreased in these cases [27]. Recent studies proposed that the combination of ECS and antidepressants can improve the antioxidant capacity and reduce oxidative stress in the neural cells [28]. We evaluated the TAC, MDA, and GSH levels as oxidative stress markers in the present study. We found ECS to have significant destructive effects on antioxidant capacity by causing oxidative stress. Our results suggest that Duloxetine improves antioxidant elements and reduces oxidative stress. Hence, we can guess that Duloxetine does not impose oxidative stress when combined with ECS, and on the contrary, it has a protective effect. In addition, similar to phenytoin, Duloxetine can effectively increase the antioxidant capacity of the brain when administered in combination with ECS. However, some limitations of this study should be addressed. First, these results need to be confirmed by clinical trials conducted on human subjects. Second, in the existing model, depression was not induced in the animal, and only the toxicity of the drug in a healthy animal was investigated. While in human studies, it is better to work on a depressed patient. Third, ECS causes cognitive impairment, better traceable in human subjects.

Conclusion

In conclusion, our findings suggest that the combination of ECS and Duloxetine is a safe therapeutic approach and has no serious adverse effects.

Competing Interest

The authors declare that they have no conflicts of interest.

References

1. Disease, G.B.D., I. Injury, and C. Prevalence, Global, regional, and national incidence, prevalence, and years lived with disability for 354 diseases and injuries for 195 countries and territories, 1990-2017: a systematic analysis for the Global Burden of Disease Study 2017. *Lancet*. 2018;392(10159): 1789-858.
2. First, M.B., Diagnostic and statistical manual of mental disorders, 5th edition, and clinical utility. *J Nerv Ment Dis*. 2013;201(9): 727-9.
3. Sanghani, S.N., G. Petrides, and C.H. Kellner, Electroconvulsive therapy (ECT) in schizophrenia: a review of recent literature. *Current opinion in psychiatry*. 2018;31(3): 213-22.
4. Olesen, M.V, et.al, Electroconvulsive stimulation results in long-term survival of newly generated hippocampal neurons in rats. *Hippocampus*. 2017;27(1): 52-60.
5. in Depression in adults: recognition and management. 2009: London.
6. Kellner, C.H, et.al, ECT in treatment-resistant depression. *Am J Psychiatry*. 2012;169(12): 1238-44.
7. Borowicz, K.K., et.al, Effect of acutely and chronically administered venlafaxine on the anticonvulsant action of classical antiepileptic drugs in the mouse maximal electroshock model. *European journal of pharmacology*. 2011;670(1):114-120.
8. Pitchot, W., G. SCANTAMBURLO, and M. Ansseau, Duloxetine in major depressed patients resistant to SSRI and/or venlafaxine. *Psychiatria Danubina*, 2010.
9. Eraslan D, et.al, Safety of electroconvulsive therapy-duloxetine combination. *The journal of ECT*. 2011;27(3):e51-2.
10. Dilbaz N, et al, The combined treatment of venlafaxine and ECT in treatment-resistant depressive patients. *International journal of psychiatry in clinical practice*. 2005;9(1): 55-9.
11. Gonzalez-Pinto A, et al, Efficacy and safety of venlafaxine-ECT combination in treatment-resistant depression. *The Journal of neuropsychiatry and clinical neurosciences*. 2002;14(2): 206-9.
12. Vollmayr B, F.A. Henn, Stress models of depression. *Clinical Neuroscience Research*. 2003;3(4-5):245-51.
13. Fling, J.L., Technical considerations of an electroconvulsive therapy apparatus, in *Multiple-Monitored Electroconvulsive Therapy*. CRC Press. 2019;41-55.
14. WMA Statement on Animal Use in Biomedical Research 2020; Available from: <https://www.wma.net/policies-post/wma-statement-on-animal-use-in-biomedical-research/>.
15. Pinna, M, et al, Clinical and biological predictors of response to electroconvulsive therapy (ECT): a review. *Neurosci Lett*. 2018;669:32-42.
16. Belmaker, R. and G. Agam, Major Depressive Disorder. *N Engl J Med*. 2008; 358:55-68.
17. Takada, J.Y., et al, Assessment of the cardiovascular effects of electroconvulsive therapy in individuals older than 50 years. *Braz J Med Biol Res*. 2005;38(9):1349-57.
18. Nomoto, K., et al, Effects of landiolol on hemodynamic response and seizure duration during electroconvulsive therapy. *J Anesth*. 2006;20(3):183-7.
19. Andrade C, S.S. Arumugham, and J. Thirthalli, Adverse effects of electroconvulsive therapy. *Psychiatric Clinics*. 2016;39(3):513-30.

20. Kranaster L, et al, Venlafaxin-associated post-ictal asystole during electroconvulsive therapy. *Pharmacopsychiatry*. 2012;45(03):122-4.
21. Ambhore A, et al, ECG series. Importance of QT interval in clinical practice. *Singapore medical journal*. 2014;55(12):607.
22. Cumurcu, B.E., et al, Total antioxidant capacity and total oxidant status in patients with major depression: impact of antidepressant treatment. *Psychiatry and clinical neurosciences*. 2009;63(5):639-45.
23. An, X. and X. Shi, Effects of electroconvulsive shock on neuro-immune responses: Does neuro-damage occur? *Psychiatry Research*. 2020: 113289.
24. Gonçalves C.L, et al, Ketamine treatment protects against oxidative damage and the immunological response induced by electroconvulsive therapy. *Pharmacological Reports*. 2021:1-11.
25. Samarghandian, S, et al, Protective effects of carnosol against oxidative stress induced brain damage by chronic stress in rats. *BMC complementary and alternative medicine*. 2017;17(1):1-7.
26. Zahedi, E., et al., The effect of electroconvulsive therapy on the levels of oxidative stress factors in the prefrontal cortex of depressed rats. *Journal of Basic and Clinical Pathophysiology*. 2018;6(2):27-31.
27. Nieoczym D, et al, Maximal electroshock induces changes in some markers of oxidative stress in mice. *J Neural Transm (Vienna)*. 2008;115(1):19-25.
28. Lee T.K., et al, Pretreated duloxetine protects hippocampal CA1 pyramidal neurons from ischemia-reperfusion injury through decreases of glial activation and oxidative stress. *J Neurol Sci*. 2016; 370:229-36.